

Diagnosis and patient pathway in lymphomas

Dr Ian Chau
Consultant Medical Oncologist
The Royal Marsden Hospital
London & Surrey

Case history 1

- 25 years old male
- May 12 presented with right supraclavicular lymphadenopathy
- Jun 12 developed lymphadenopathy in both axillae
- Developed night sweats and weight loss



What clinical features are important to elicit in patients presenting with lymphadenopathy?

- 1) Weight loss
- 2) Night sweats
- 3) Travel history
- 4) Household pets
- 5) All of the above



NICE guidance for suspected haematological cancers

- Primary healthcare professionals should be aware that haematological cancer can present with a variety of symptoms that may have a number of different clinical explanations.
- Combinations of the following symptoms and signs may suggest haematological cancer and warrant full examination, further investigation (including a blood count and film) and possible referral:
 - Fatigue
 - recurrent infections
 - bone pain
 - alcohol-induced pain
 - abdominal pain
 - lymphadenopathy
 - splenomegaly
 - bleeding
 - drenching night sweats
 - fever
 - weight loss
 - generalised itching
 - breathlessness
 - bruising



What would be your initial investigations in patients with unexplained lymphadenopathy?

- A) Full blood count
- B) Ultrasound of the lymph node
- C) ESR
- D) Serum rheumatoid factor
- E) Monospot test

Vote 1 for A, B and C

Vote 2 for A, B, C and D

Vote 3 for all the above

Vote 4 for A, B, C and E

Vote 5 for A, D and E



Investigation and referral of lymphadenopathy (NICE guidance)

- Investigation of patients with unexplained lymphadenopathy should include a full blood count, blood film and erythrocyte sedimentation rate, plasma viscosity or C-reactive protein (according to local policy).
- Any of the following additional features of lymphadenopathy should trigger further investigation and/or referral:
 - persistence for 6 weeks or more
 - lymph nodes increasing in size
 - lymph nodes greater than 2 cm in size
 - widespread nature
 - associated splenomegaly, night sweats or weight loss.



How common is lymphadenopathy in general population?

- 1) 6%
- 2) 10%
- 3) 1%
- 4) 60%
- 5) 0.6%



Background to lymph node diagnostic clinic (LNDC)

- Lymphadenopathy (LA) is common affecting patients of all ages.
- An annual incidence of 0.6-0.7% has been estimated for the general population



Background

- Critical tasks are:
 - differentiate benign from malignant lymph nodes
 - identify serious medical conditions that require specific treatment
 - reassure patients with benign reactive lymphadenopathy (BRL) or self-limiting disease



Factors in assessing lymphadenopathy

- General factors such as age, sex, socio-economic conditions
- Sites of lymph nodes
- Associating symptoms and signs
- Epidemiological clues such as occupational exposures, recent travel or high risk behaviours



Background

- Cancer is perhaps the disease people fear most
- In primary care setting, the prevalence of malignancy were 0-1.3%
- This compared with lymph node biopsies series with malignancy rate as high as 40%
- Serious non-malignant conditions presenting with LA
- Infections such as TB and HIV
- Immune induced injury disorders such as SLE, sarcoidosis and rheumatoid arthritis



Primary aim of lymph node diagnostic clinic (LNDC)

- Current referral pattern varies
- Lymph node diagnostic clinic was set up to reach rapid diagnosis in a concerted multidisciplinary approach in patients with lymphadenopathy

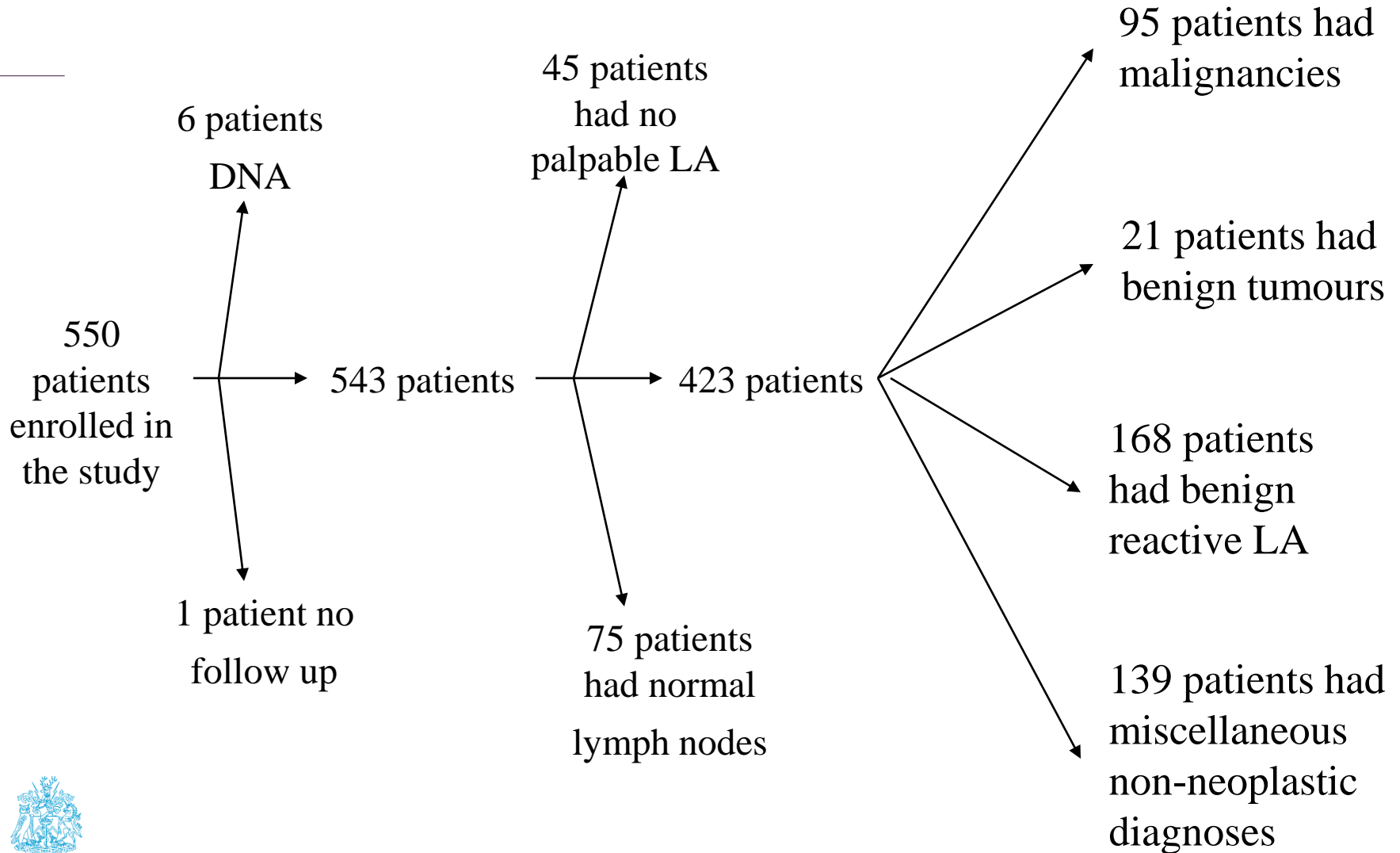


Results

- N=550 patients
- Median age was 40 (range 14-90)
- Median time between initial referral and first clinic visit was 6 days (including weekends and public holidays)
- 75% seen within one week of referral and 97% within two weeks.



Study flow diagram



Malignancies

-
- Malignancy pick up rate of 17.3%



Lymphoproliferative disorders

Diagnosis	Number (n=62)
Hodgkin's disease	19
Diffuse large B cell	18
Follicular	10
B-CLL	4
Mantle cell	3
T cell	3
Small lymphocytic lymphoma	3
PTLD	1
Unclassified	1



Metastatic tumours

Diagnosis	Number (n=33)
Head & Neck	10
Breast	3
Lung	4
Melanoma	3
Prostate	2
Thyroid	2
Oesophagus	1
Seminoma	1
Unknown Primary	3
Others	4



Time to malignancy diagnosis

- Median time from first clinic visit to establishment of malignant diagnosis was 16 days (range=0-121 days)



Which lymph node region is most concerning for malignancy?

- 1) cervical lymphadenopathy
- 2) supraclavicular lymphadenopathy
- 3) axillary lymphadenopathy
- 4) inguinal lymphadenopathy



Presenting lymph node regions

Lymph node Regions	Whole cohort (n=550)	Malignancy
Head & neck	254 (46.2)	35 (13.8)
→ Supraclavicular	35 (6.4)	12 (34.3)
Axillary	53 (9.6)	8 (15.1)
Inguinal	41 (7.5)	7 (17.1)
→ ≥ 2 regions	87 (15.8)	30 (34.5)
Extranodal	80 (14.5)	3 (3.8)



() denotes %

Benign tumours

Diagnosis	Number (n=21)
Pleomorphic adenoma	10
Warthin's tumour	4
Schwannoma	3
Thyroid adenoma	3
Carotid body tumour	1



Miscellaneous non malignant diseases

- 139 cases
- Most are self-limiting and require no further treatment
- Some are serious and require specialist care



Bacterial infections

Diagnosis	Number (n=19)
TB	12
Streptococcus	2
Corynebacterium	1
Moraxella	1
Bartonella	3



Other infections and infestations

Diagnosis	Number (n=28)
HIV	4
EBV	5
CMV	1
Hepatitis C	1
Toxoplasmosis	15
Pediculosis/dermatophytosis	2



Miscellaneous diagnoses

Diagnosis	Number (n=139)
Infection and infestations	47
Immune mediated injury disorders	
SLE	6
Sarcoidosis	6
Rheumatoid arthritis	1
Primary skin diseases	5
Others	73



Diagnostic tools

- To detect malignancy, the following tools were used:
 - US
 - FNA
 - CXR
 - CT/MRI



Accuracy of investigations to detect malignancy

Tests (n=)	Sensitivity	Specificity	Positive Predictive Value	Negative Predictive Value	Accuracy
US (154)	100%	97%	69%	100%	97%
FNA (289)	49%	97%	84%	84%	84%



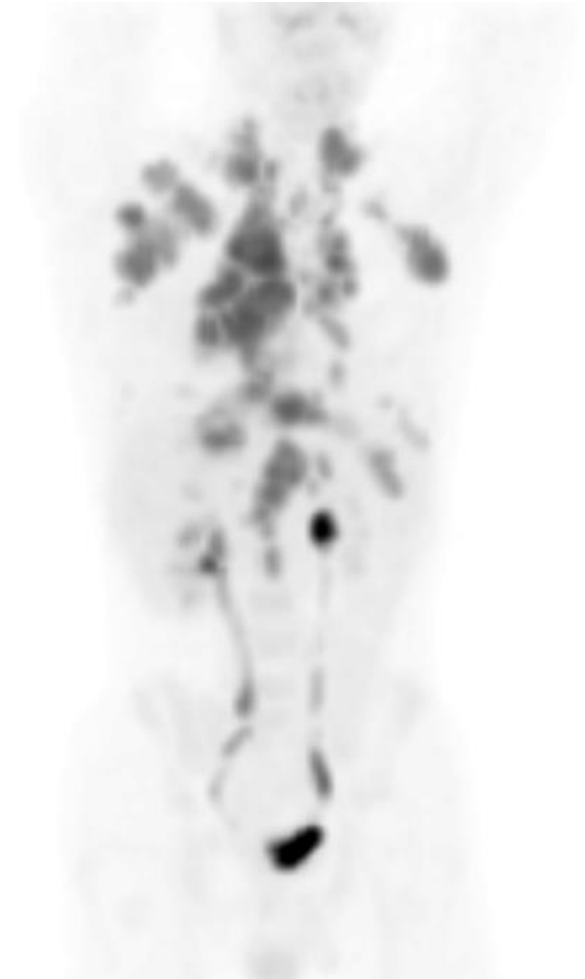
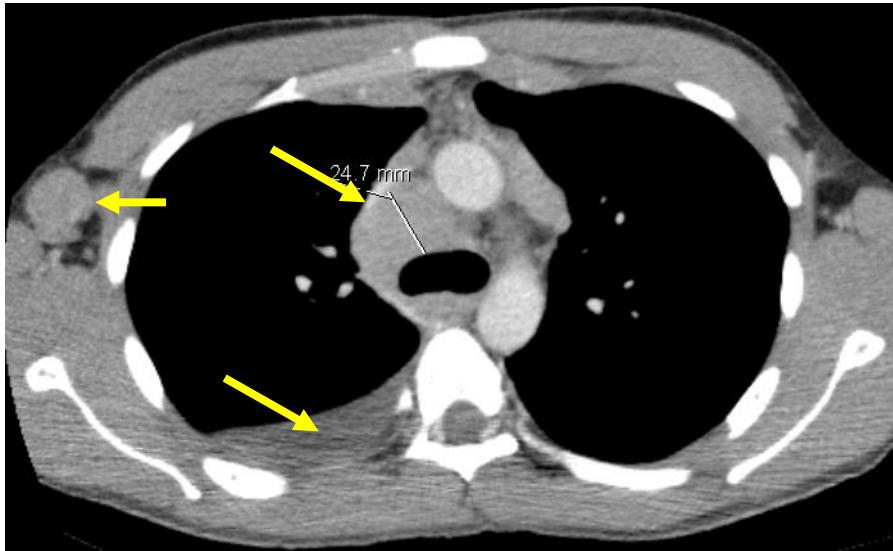
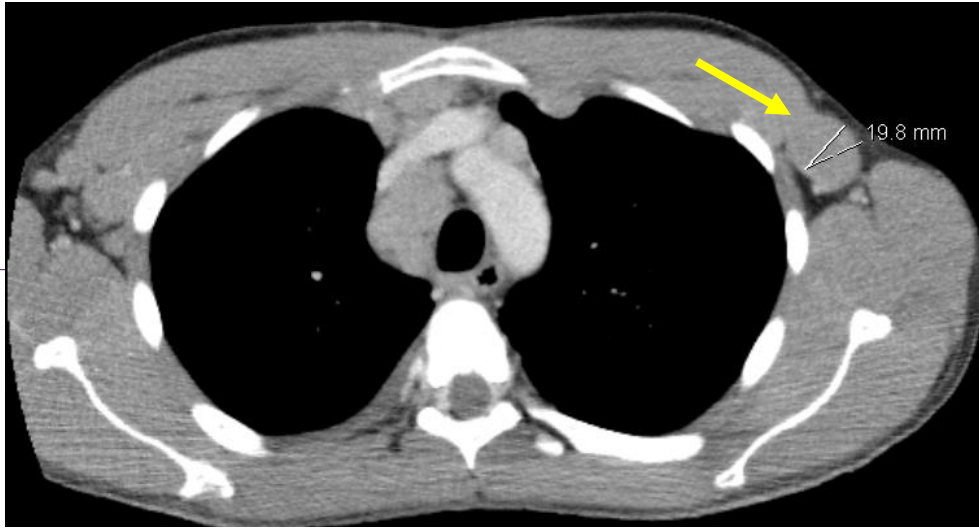
Case history 1

- 25 years old male
- May 12 presented with right supraclavicular lymphadenopathy
- Jun 12 developed lymphadenopathy in both axillae
- Developed night sweats and weight loss
- Went to Mexico for holidays in August. Symptoms continued. Treated as chest infection.
- CXR → small right sided pleural effusion. Prescribed amoxicillin
- Aug 12 CT scan →



Staging CT and PET

Stage IIIB



Case history 1 (cont'd)

- Aug 12 CT → multiple enlarged lymph nodes in both axillae, mediastinum and upper abdomen
- Initial needle biopsy → inconclusive
- Sep 12 excision lymph node biopsy → nodular sclerosing Hodgkin's lymphoma reported by the referring hospital.
- Bone marrow biopsy performed
- 19 September Referred to Royal Marsden Hospital
- PET scan → extensive FDG positive lymphadenopathy above and below the diaphragm as described, consistent with stage IIIB disease
- ABVD (doxorubicin, bleomycin, vinblastine and dacarbazine) chemotherapy planned

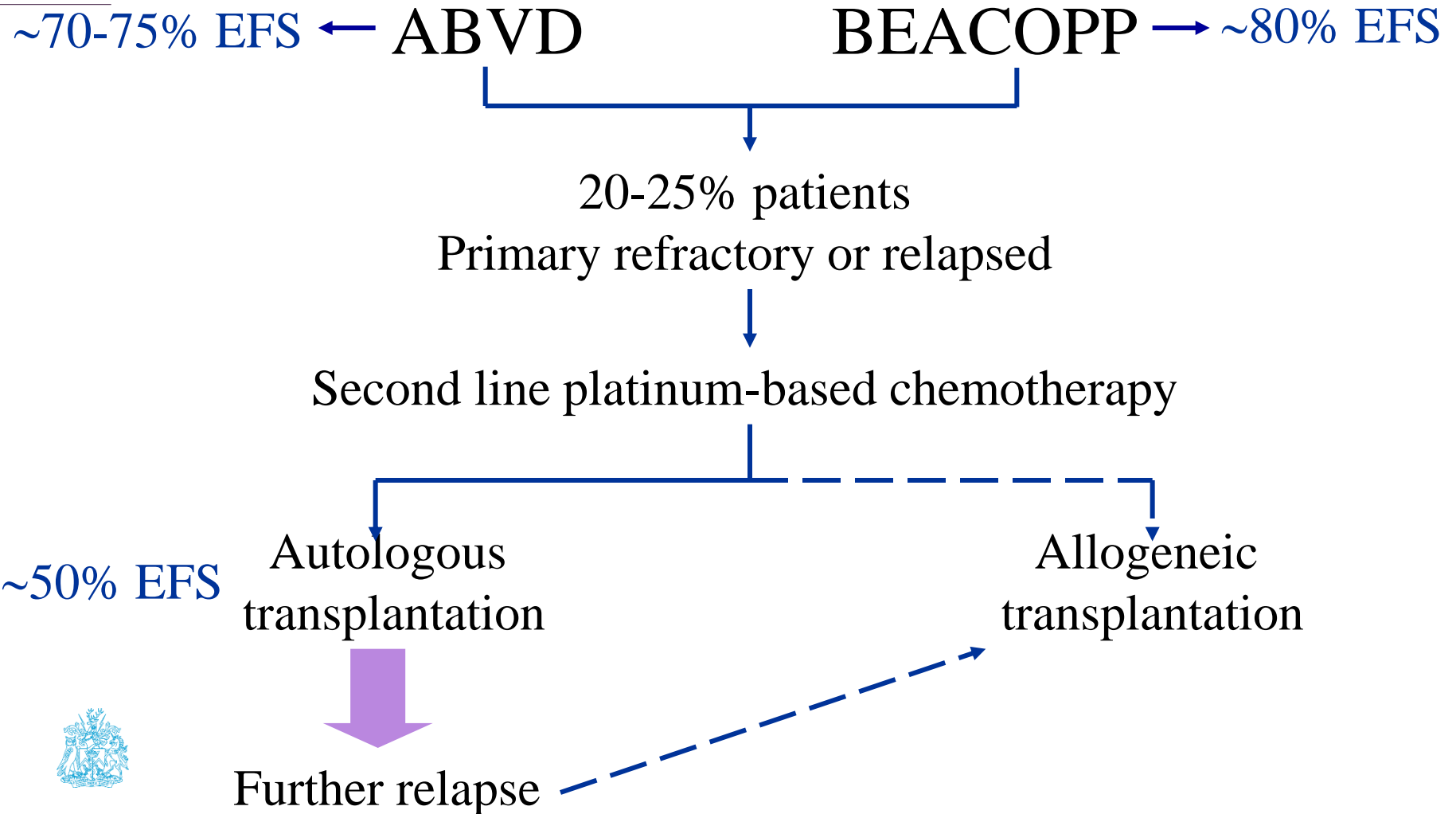


Case history 1 (cont'd)

- Bone marrow biopsy confirmed to be negative
- Histology review → Hodgkin's lymphoma revised to angioimmunoblastic T cell lymphoma
- Enrolled into CHEMO-T trial – randomised to GEM-P chemotherapy.



Treatment paradigm for advanced stage Hodgkin's lymphoma



Peripheral T cell lymphoma (PTCL)

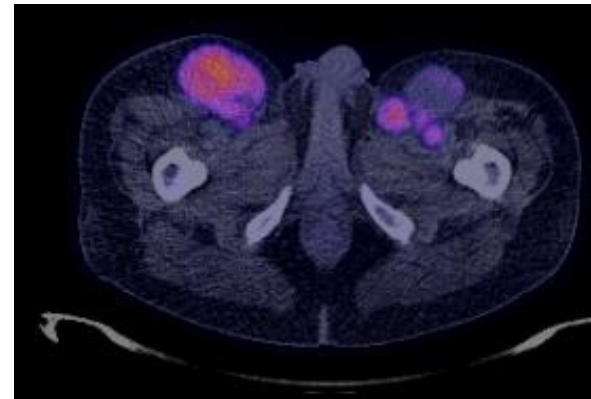
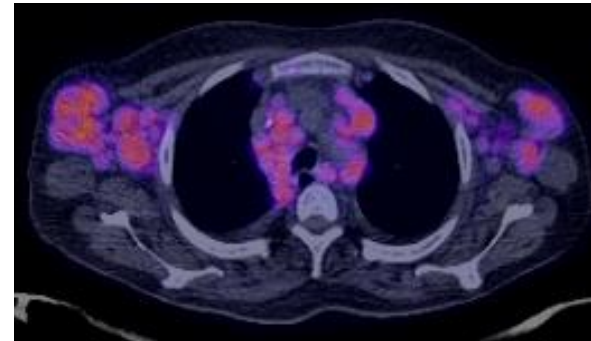
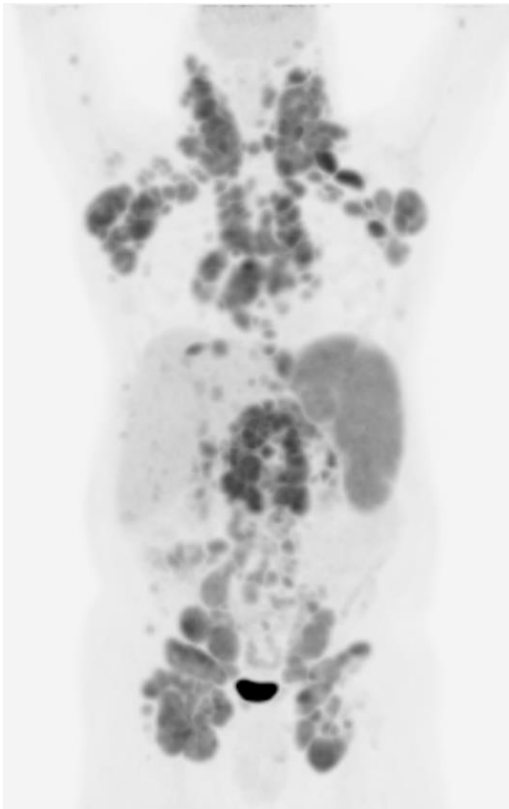
PTCL not otherwise specified (NOS)

Angioimmunoblastic T cell lymphoma

Anaplastic large cell lymphoma (ALCL)

-ALK positive

-ALK negative



Peripheral T cell lymphoma (PTCL)

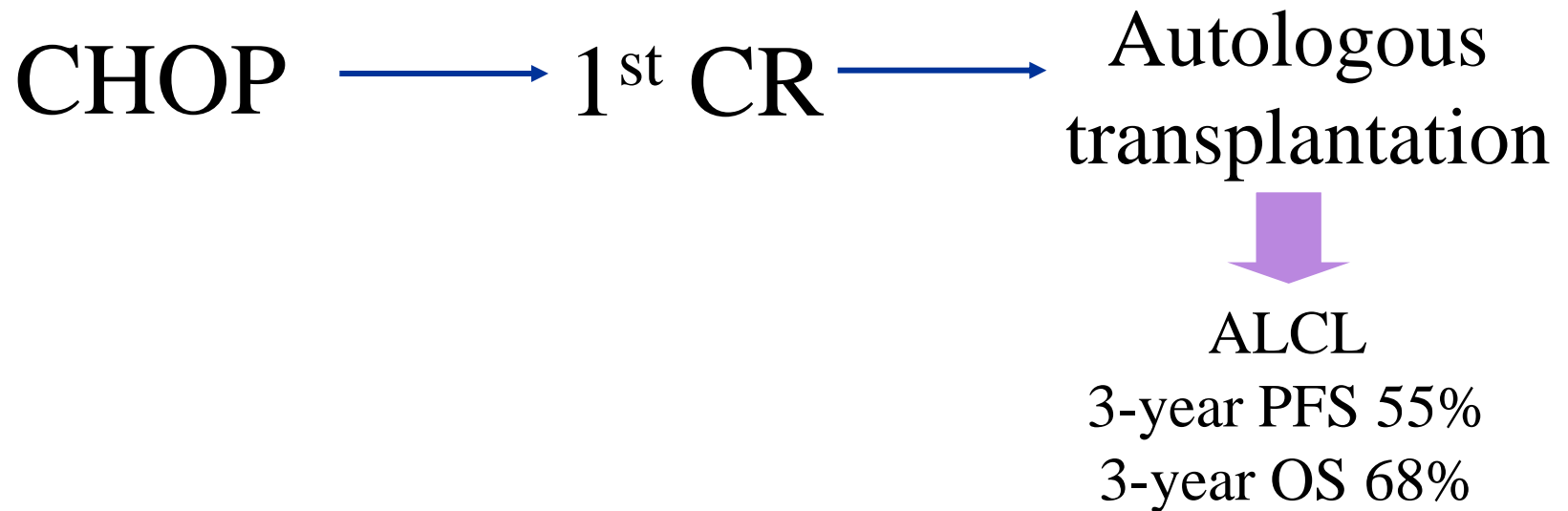
PTCL not otherwise specified (NOS)

Angioimmunoblastic T cell lymphoma

Anaplastic large cell lymphoma (ALCL)

-ALK positive

-ALK negative



Salvage therapy

Hodgkin's lymphoma

PTCL

Relapsed after or unsuitable for
transplantation

Gemcitabine

Vinorelbine

HDAC inhibitors

e.g. panobinostat

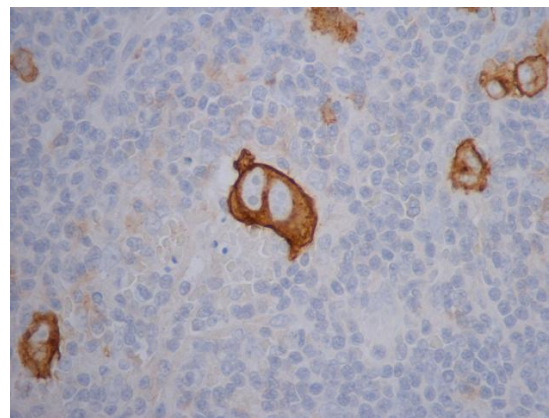
Gemcitabine

Pralatrexate

Romidepsin

CD30 +ve
lymphoma cell

ALCL



BRENTUXIMAB

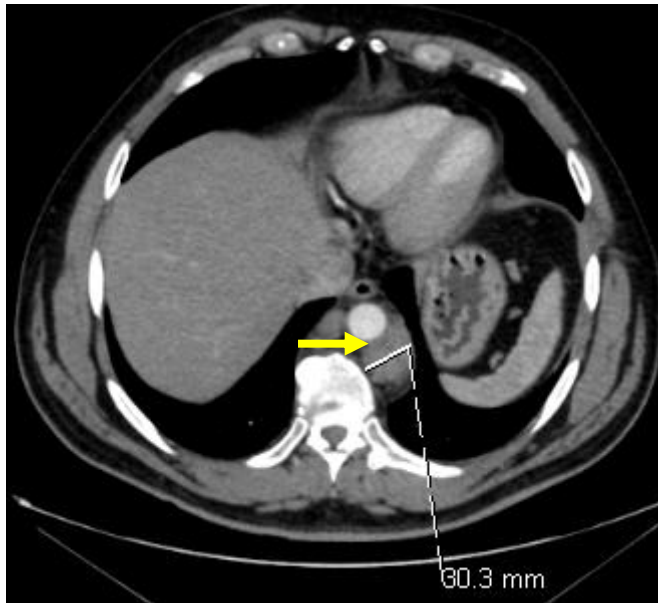
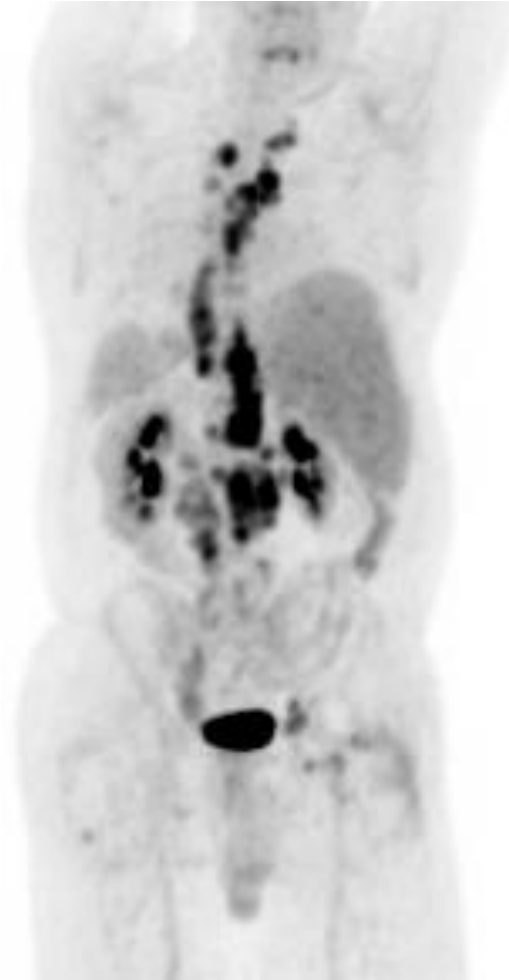
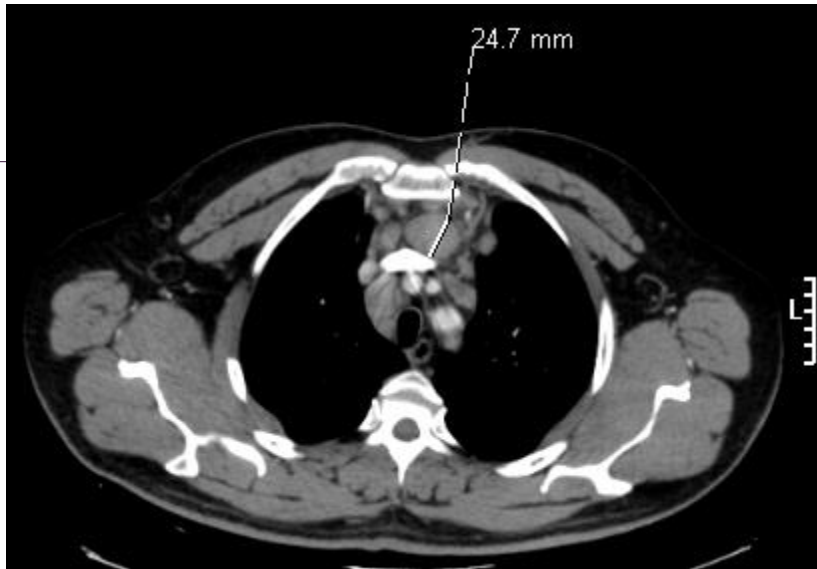

Case history 2

- 49 years old male
- Easter 12 presented with vomiting and pain across right flank and abdomen while on holiday in Barbados
- Pain recurred after returning to the UK
- Consulted GP
- US → gallstones and abdominal lymph nodes
- June 2012 Underwent laparoscopic cholecystectomy and lymph node biopsy
- Retroperitoneal mass biopsy, liver biopsy and gall bladder only showed chronic active cholecystitis and previous fat necrosis (histology reviewed at RMH)
- July 2012 Further biopsy of left femoral lymph node → follicular lymphoma grade 1
- Pain free and symptom free by August 2012
- Aug 12 CT and PET scans →



CT and PET showed stage IIIA disease



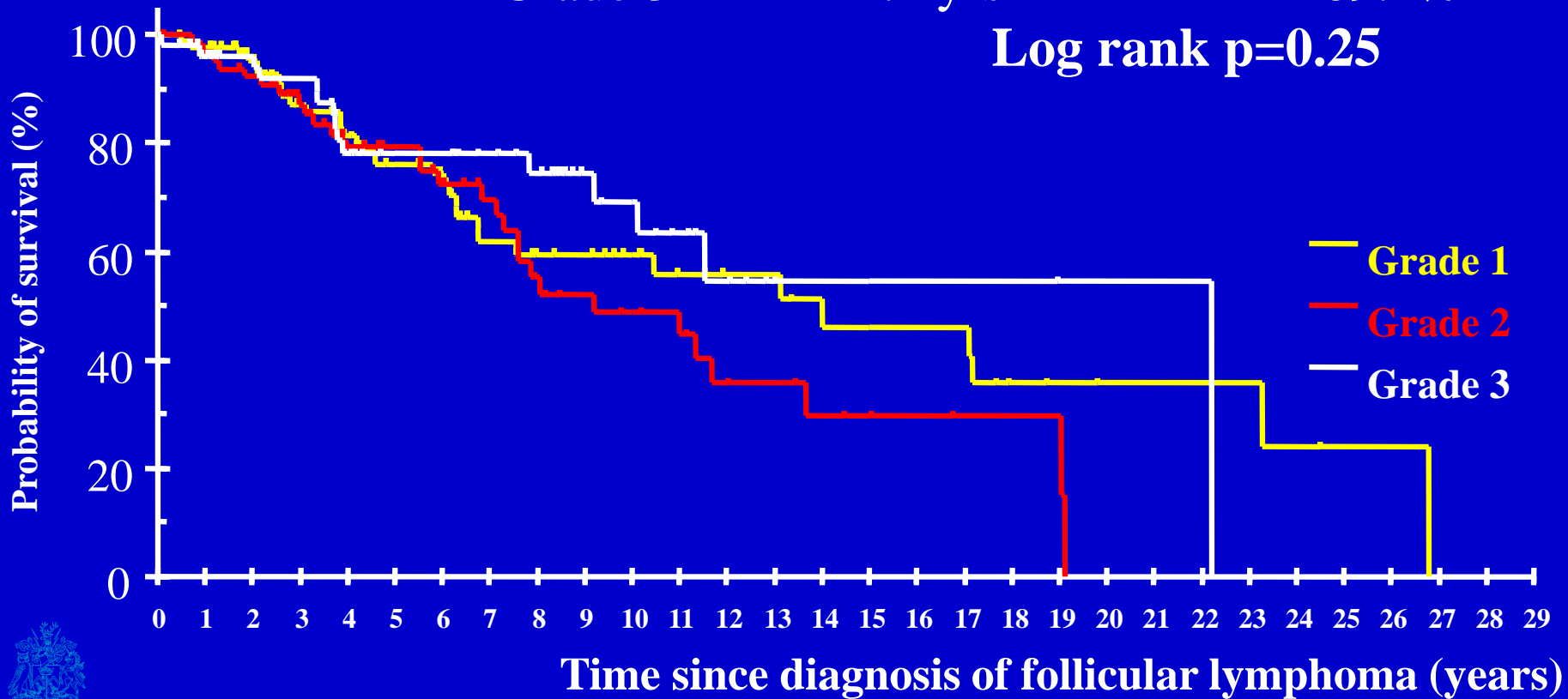
Case history 2 (cont'd)

- Asymptomatic patients with stage III disease
- Watch and Wait versus initiate immediate treatment



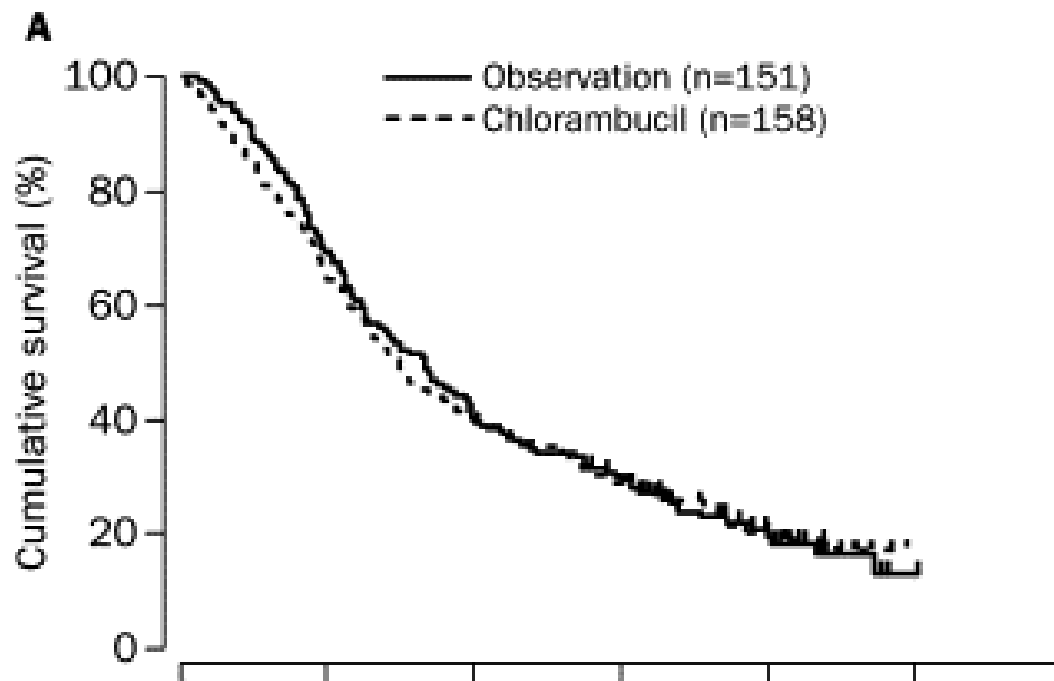
Overall survival for patients with follicular lymphoma

	Median survival	10 yr survival
Grade 1	14 yrs	59.5%
Grade 2	9.2 yrs	48.7%
Grade 3	22.2 yrs	69.2%



Case history 2 (cont'd)

- Asymptomatic patients with stage III disease
- Watch and Wait versus initiate immediate treatment

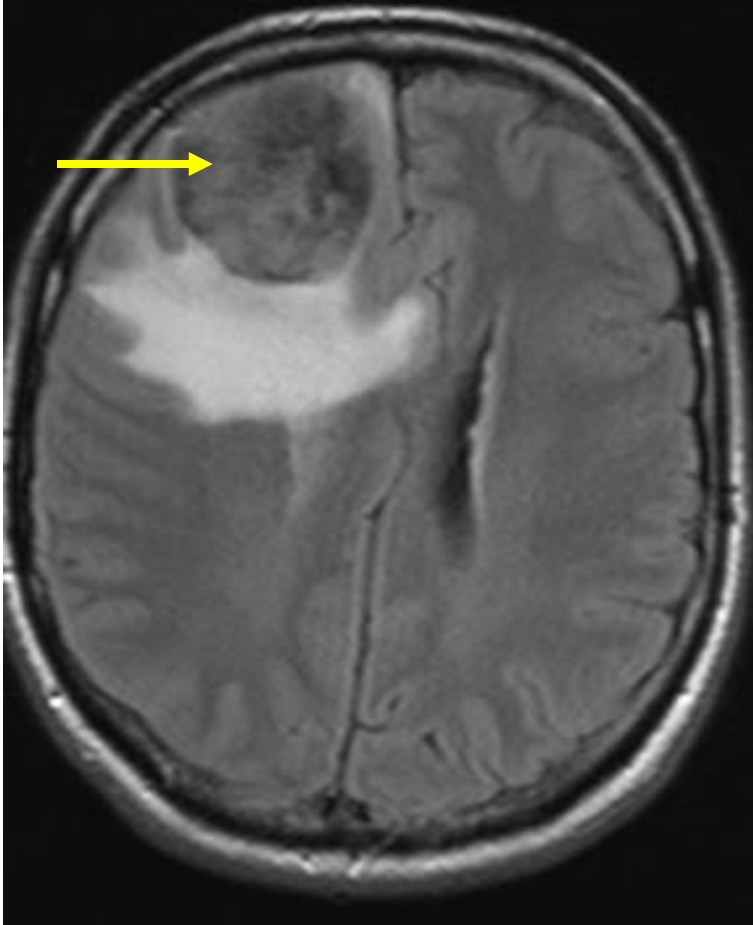
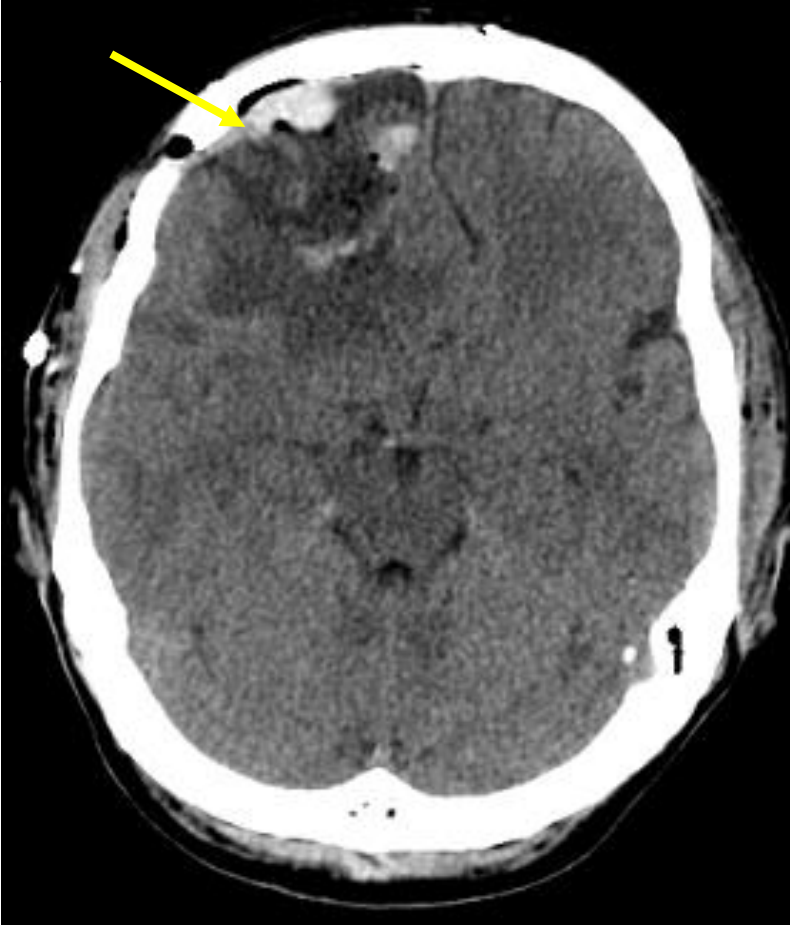


Case history 3

- 52 years old male
- Jun 13 presented with headache while on holiday in Turkey
- Headache continued and started to have vomiting
- Attended GP and subsequently A&E
- Jul 12 CT and MRI scans →



CT and MRI showed an intracranial mass



Case history 3 (cont'd)

- Referred to local neurosurgical centre
- 2 Jul Underwent craniotomy with total excision of the lesion
- Histology → Primary CNS diffuse large B cell lymphoma
- Aug 13 Referred to RMH
- HIV serology negative
- Sep 13 Commenced on high dose methotrexate and cytarabine



Conclusions

- Lymphadenopathy has a wide range of causes – both benign and malignant
- Persistent, supraclavicular and multiple regions are features suspicious of malignant lymphadenopathy
- Many lymphomas do not present with lymphadenopathy
- High cure rate in some lymphomas and the indolent nature of other lymphomas mean treatment toxicities (short and long term) need to be carefully balanced with treatment efficacy



Acknowledgement

National Health Service funding to the
National Institute for Health Research
Biomedical Research Centre

